at third part of the duodenum, instead of the second. The major papilla could not be cannulated via guide wire as the wire repeatedly deviated towards the pancreatic duct and ultimately sphincterotomy was performed. Again, the wire had the tendency to deviate towards the pancreatic ductus, so pancreatogram was performed. When contrast medium was given, the presence of incomplete division was confirmed but surprisingly the biliary system was viewed as well. The distal part of the CBD recognized to have a cystic dilatation and was communicating perpendicularly with the ventral pancreatic duct via a thin channel. And thereafter it was opening to duodenum via non-dilated common long duct. (**Figure-1b**). Sphincterotomy of the major papilla was done. During ERCP it was observed that bile was present in minor papilla, so cholangiogram was also performed through it and sphincterotomy of the minor papilla was also done.

Discussion

According to Komi's classification of anomalous union between pancreatic and bile ducts, our patient was classified as a Type III-c2.[2] One can speculate that the patient was asymptomatic throughout her life due to adequate drainage of pancreatic and biliary secretions via both the dorsal and the common long ducts and the obstruction of this complex network by a calculus or a protein plug originating from biliary system or pancreas precipitated her attack of acute pancreatitis and cholangitis.

This case suggests that this anomaly might be more common, some cases being asymptomatic, than previously estimated in general population. ERCP is the gold standard in the diagnosis of such pancreaticobiliary ductal variations and is the best method to obtain adequate information prior to any surgical intervention, as even MRCP had failed to document this variation in our case.

SELÇUK DİŞİBEYAZ
ERKİN ÖZTAŞ
UFUK BARIŞ KUZU
NURETDİN SUNA
ERTUĞRUL KAYAÇETİN

Department of Gastroenterology, Turkiye Yuksek Ihtisas Education and Research Hospital, Ankara, Turkey.

Correspondence: Ufuk Barış Kuzu
Email: ubarisk@gmail.com

References

1. Yamao K, Mizutani S, Nakazawa S et al. Prospective study of the detection of anomalous connections of pancreatobiliary ducts during routine medical examinations. *Hepatogastroenterology*. 1996;43(11):1238-45.
2. Komi N, Takehara H, Kunitomo K et al. Does the type of anomalous arrangement of pancreaticobiliary ducts influence the surgery and prognosis of choledochal cyst? *J Pediatr Surg*. 1992;27(6):728-31.

Carcinosarcoma of the gallbladder presenting as a hemorrhagic hepatoduodenal cyst

Carcinosarcoma of the Gall Bladder (CSGB) is an extremely rare neoplasm and it is characterized by the presence of both carcinomatous and sarcomatous components. It usually occurs in many organs including the uterus, lung, oesophagus, kidney and pancreas.[1] Carcinosarcomas account for less than 1% of all gall bladder malignancies.[1,2]

Case Report

We document a case of a 47 year old lady who presented with acute abdominal pain, associated with abdominal distension and discomfort present for fifteen days. Her laboratory investigations revealed an increase in the alkaline phosphatase and gamma glutamyltranspeptidase levels to 146 IU/L and 183 IU/L, respectively. A tender abdominal lump was palpated in the right hypochondrium

and epigastrium. Contrast enhanced CT scan of the abdomen showed a heterogeneously enhancing mass lesion involving the neck of the gallbladder and infiltrating into the surrounding liver parenchyma (segment V/ VI). A large peri-lesional hematoma measuring 13x12x12 cm with areas of active contrast extravasation was noted in the hepatoduodenal ligament (HDL). This lesion was seen to compress adjacent structures. A pre-operative diagnosis of advanced carcinoma gallbladder was made and the patient underwent extended cholecystectomy with excision of HDL cystic mass. The gallbladder measured 9.5 cm in length and 3.0 cm in diameter. An ill defined mass was seen arising from the region of the neck and measuring 3.5x3x3 cm in size. A fragmented cyst wall of size 13x9 cm with maximum thickness of 1 cm was also received which showed focal myxoid areas and marked congestion. Microscopy showed the tumour was composed of epithelial and spindle cell components merging with each other. The tumour cells lining the glands, solid nests and sheets were round to polygonal in shape with sharp cytoplasmic boundaries, marked degree of pleomorphism and moderate amount of eosinophilic cytoplasm. The nuclei were hyperchromatic; with coarse chromatin and prominent nucleoli, a few showed intranuclear inclusions. Many bizarre giant cells were seen. Focal areas of squamous differentiation were also noted with occasional keratin pearl formation. The mesenchymal tumour component showed spindle cells and extensive myxoid change. Mitosis was brisk, 3-6/ hpf including many atypical mitotic figures. The cyst wall showed a tumour with hyper and hypocellular areas composed of plump to elongated spindle cells in sheets and fascicles and with extensive myxoid change in the background. The spindle cells had similar morphology as described above. Areas of haemorrhagic necrosis were also seen. Wedge biopsy of the liver showed tumour deposits predominantly composed of epithelial component. Tumour metastasis to the pericholedochal lymph node was seen.

Immunohistochemistry showed strong cytoplasmic positivity for pancytokeratin, CK 7, MUC 1 and epithelial membrane antigen in the epithelial component along with cytoplasmic positivity for Alcian blue. The spindle cell component showed strong cytoplasmic positivity for vimentin. A diagnosis of carcinosarcoma of the gall bladder was given. The hemorrhagic HDL cyst was reported as infiltration by sarcomatous component of the tumour while wedge of liver showed tumour infiltration by the epithelial component. (**Figure 1 a-d**)

Discussion

Carcinosarcoma is a biphasic tumour, presenting with both epithelial and mesenchymal components which are closely intermixed with each other.[3] The epithelial component is most commonly an adenocarcinoma. The mesenchymal component is usually a homogenous spindle cell sarcoma and can show heterologous elements such as cartilage, muscle and bone.

Two opposing theories were initially postulated to explain the origin of these tumours. The multiclonal or convergent hypothesis proposed that these tumours are derived from two or more stem cells of separate epithelial and mesenchymal origin. According to the monoclonal or divergent hypothesis, carcinomatous and sarcomatous elements are derived from a single pluripotential stem cell that develops divergent differentiation along separate epithelial and mesenchymal pathways. Dacic et al in 2002 performed extensive comparative genotypic

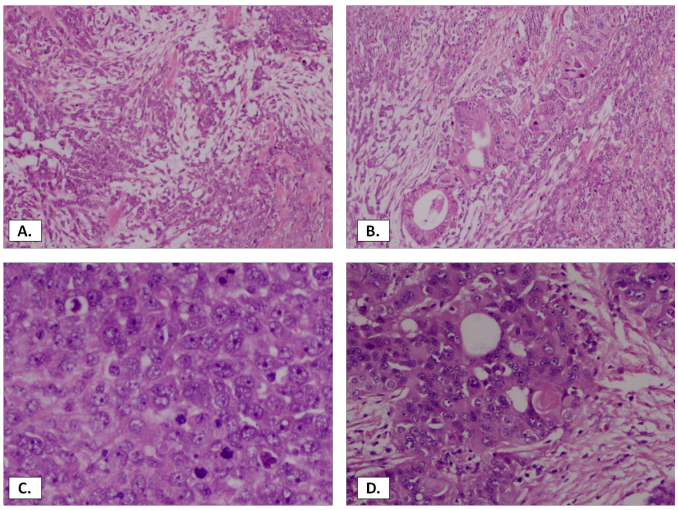

Figure 1: (A) Spindle cell component of the tumour (H-and-E,-10x). (B) Intermingling of malignant glandular and mesenchymal component (H-and-E,-10x). (C) High grade areas with brisk mitosis (H-and-E,-20x). (D) Foci of squamous epithelium.

analysis using tissue micro-dissection in pulmonary carcinosarcomas. They found identical allelic losses shared by each tumor component, without discordant losses. This was consistent with the hypothesis that the carcinomatous and sarcomatous components were derived from a single pluripotent stem cell or the divergent hypothesis.[4] Alternatively, ultra-structural studies of carcinosarcoma have revealed the presence of tonofibrils and desmosomes not only in the epithelial component but also in the sarcomatous component, suggesting derivation of the sarcomatous component from the carcinomatous component favouring the metaplastic or conversion theory.[5]

Zhang et al, in their study, reported that patients with tumours that were smaller than 5 cm had a longer survival and that the tumour size should therefore be considered as a major component in the future staging system for CSGB, although genetic variations, early detection (stage I or stage II) and a more extensive surgery could also contribute to a better prognosis. They also indicated that the presence of gallstones, epithelial and mesenchymal component types, age and sex were of little prognostic value.[6] Race (Japanese versus non Japanese) and tumour size were important prognostic factors in carcinosarcoma of gallbladder.[6]

JYOTSNA SINGH[1]
SUNAYNA MISRA[1]
CHHAGAN BIHARI[1]
VINIYENDRA PAMECHA[2]
ARCHANA RASTOGI[1]

[1]Department of Pathology, [2]Department of HPB Surgery, Institute of Liver & Biliary Sciences, Delhi, India.

Correspondence: Archana Rastogi
Email: drarchanarastogi@gmail.com

References

1. Huguet KL, Hughes CB, Hewitt WR. Gallbladder carcinosarcoma: a case report and literature review. *J Gastrointest Surg*. 2005; 9: 818-21.
2. Khanna M, Khanna A, Manjari M. Carcinosarcoma of the Gallbladder: A Case Report and Review of the Literature. *Jour of Clin Diagn Res*. 2013;7:560-62.
3. Agarwal T, Jain M, Goel A, Visayaragavan P, Gupta RK. Carcinosarcoma of the gallbladder. *Indian J Pathol Microbiol*. 2009;52:244-45.
4. Dacic S, Finkelstein SD, Sasatomi E, Swalsky PA, Yousem SA. Molecular pathogenesis of pulmonary carcinosarcoma as determined by microdissection-based allelotyping. *Am J Surg Pathol*. 2002;26:510-16.
5. Haraguchi S, Fukuda Y, Sugisaki Y, Yamanaka N. Pulmonary carcinosarcoma: immunohistochemical and ultrastructural studies. *Pathol Int*. 1999;49:903-8.
6. Zhang L, Chen Z, Fukuma M, et al. Prognostic Significance of Race and Tumor Size in Carcinosarcoma of Gallbladder: a Meta-Analysis of 68 Cases. *Int J Clin Exp Pathol*. 2008;1:75-83.