differentiated. MRCP confirms the same by demonstrating complete absence of duct of Santorini, obviating the need for ERCP which is an invasive procedure.

Imaging features of groove pancreatitis include the presence of crescentic sheet-like soft tissue in the pancreaticoduodenal groove. Few tiny dystrophic cysts may also be found in the medial wall of the duodenum, as in our case. No involvement of the head of pancreas is seen in the "pure" form of groove pancreatitis. As opposed to it, the head of pancreas is involved in the segmental form, often presenting with mass-like enlargement of the head. Every effort has to be made to differentiate it from adenocarcinoma of head of pancreas, which may not be possible in every case[5].

The co-occurrence of two extremely rare entities, that is, complete agenesis of the dorsal pancreas (ADP) and groove pancreatitis, is hitherto unknown, this being the first such case.

References

1. Kabnurkar R, Rokade ML, Bandekar K *et al*. Incidentally detected agenesis of dorsal pancreas on PET/CT: Case report and review of literature. Indian J Nucl Med 2017;32:33-5.
2. Ranjan K Sahoo, Srikant K. Dhar, Pratap Beher Dorsal pancreas agenesis - a rare case report, Eur. J. Anat. 19 (3): 291-293 (2015)
3. Thakur S, Jhobta A, Sharma D *et al* MR in complete dorsal pancreatic agenesis: Case report and review of literature Indian J Radiol Imaging 2014; 24:156□9
4. Manoranjan Mohapatra, Sanjeet Mishra, Prakash Chandra Dalai *et al* Imaging Findings in Agenesis of the Dorsal Pancreas. Report of Three Cases JOP. J Pancreas (Online) 2012 Jan 10; 13(1):108-114.
5. Siva P. Raman Safia N. Salaria,Ralph H. Hruban *et al* Groove Pancreatitis: Spectrum of Imaging Findings and Radiology- Pathology Correlation AJR 2013; 201:W29–W39

Ileo-Ileal Knotting: An Unusual Cause of Intestinal Obstruction

Robin Kaushik[1]
Rajpal Singh Punia[2]

Department of [1]Surgery1 and [2]Pathology, Government Medical College and Hospital, Chandigarh, India.

Corresponding Author: *Dr Robin Kaushik*
Email: robinkaushik@yahoo.com

First described nearly 500 years ago by Riverius in the 16th century, intestinal knotting remains an uncommon cause of mechanical bowel obstruction.[1] Rotation of a segment of the intestine, along with its mesentery, leads to closed-loop obstruction. Compromise of the vascularity results in the rapid onset of ischemia of the affected segment.

Various types of intestinal knots have been described - ileo-sigmoid, appendico-ileal, ileo-caecal, ceco-sigmoid, around a Meckel's diverticulum,and ileo-ileal.[1-3] Ileo-sigmoid knotting (ISK) is by far the most frequently encountered, in which loops of ileum and distal jejunum twist around thebase of a narrow sigmoid colon. Factors associated with ISK and intestinal knotting, in general, are a freely mobile small intestine, redundant sigmoid colon, long and narrow mesocolon, high fiber diet, and ingestion of a single daily meal.[1-3] Unfortunately, there is a paucity of literature on ileo-ileal knotting, and only 9 cases have been reported in the literature, to our knowledge.[2,4]

We report another such case of this rare cause of intestinal obstruction that occurred in a patient who underwent laparoscopic cholecystectomy at our Institute, and review relevant literature.

Case Report

A 65 year old lady underwent elective laparoscopic cholecystectomy (LC) at our hospital for symptomatic gallstones. A standard four-port LC was performed under general anesthesia with the first (infra-umbilical) port being placed by an open technique using the umbilical

pillar. Laparoscopic examination of the abdomen was normal, and then cholecystectomy was performed, with gallbladder removal via the epigastric port, without complications and discharged the next day. On follow up visit to our outpatient clinic, she complained of occasional abdominal pain. Abdominal examination was normal, and she was advised analgesics on as needed basis.

On the 15th post-operative day, she presented to the emergency in the evening with complaints of abdominal distension and vomiting; there was no fever, tachycardia, or abdominal rebound tenderness, but there was a fullness in the right lower abdomen. She was managed conservatively with suspicion of post LC bile leak, ductal injury, or acute pancreatitis. Ultrasound of the abdomen did not reveal any collection and we proceeded with a contrast-enhanced computerized tomography (CECT) scan of the abdomen the next day, which revealed a grossly patent ductal system and a healthy pancreas. There was mesenteric stranding along with dilatation of the small bowel up to a transition zone beyond which dye could not pass, but no mass or intra-abdominal collections were seen. The patient developed fever, tachycardia, and abdominal rebound the next day, and was taken up for emergency surgery at the earliest.

Laparotomy was performed by a midline incision, and minimal dirty, serosanguinous fluid was seen, along with dilatated jejunal and ileal loops. On further exploration, a firm lump was felt in the distal ileum, about two feet proximal to the ileocecal junction (**Figure 1**). Upon delivery through the midline, a loop of the ileum was found to have twisted upon itself, and its mesentery, to cause strangulation obstruction. A part of this loop was already blackened and gangrenous with impending perforation. The ileum bearing this 'knot' as well as unhealthy bowel adjacent to it were resected (**Figure 2**). Exploration of the abdomen did not reveal any other pathology, and we were also able to visualize the common bile duct and the site of clips on the cystic duct during the previous LC. An ileostomy (as well as mucus fistula) was fashioned in the right lower abdomen, and the abdomen closed.

The patient remained well in the post-operative period and, at last follow up, was scheduled for the elective restoration of bowel continuity. Histopathology of the resected specimen revealed oedematous mucosa and submucosa with transmural infarction, congested blood vessels along with acute inflammatory cellular infiltrate.

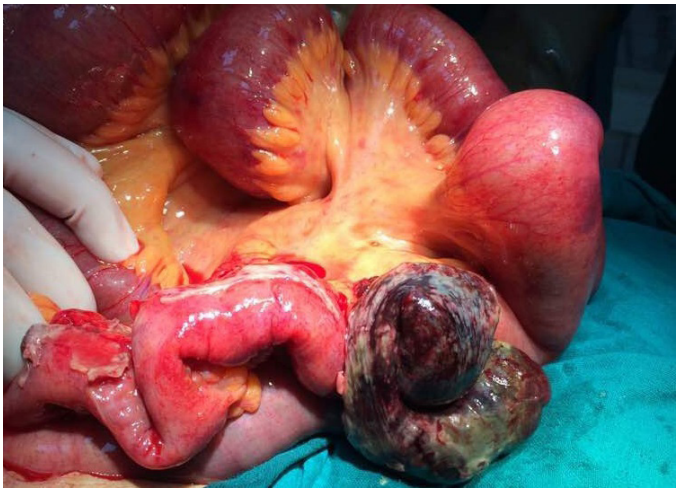

Figure 1: Intraoperative photograph showing ileo-ileal knot with gangrenous changes.

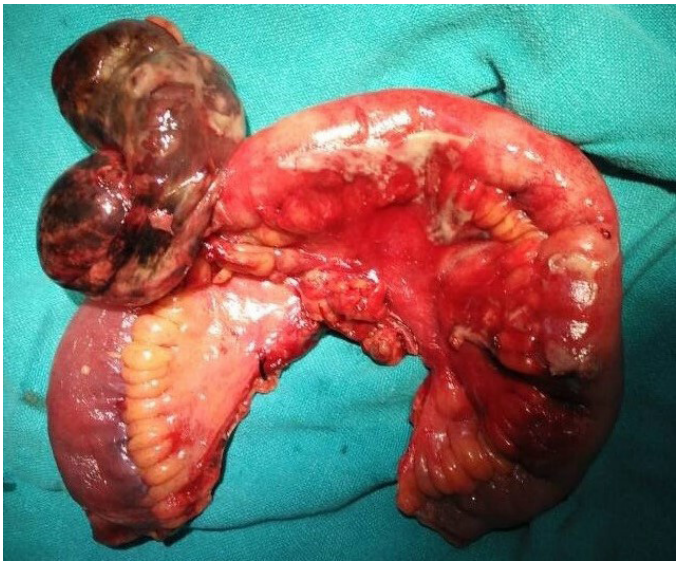

Figure 2: Resected specimen of ileum showing the twisted loops of ileum.

Discussion

LC is associated with its particular group of complications, but the present case of ileal knotting occurring post-LC is probably coincidental rather than as a consequence of LC. The etiology of ileo-ileal knotting is poorly understood, and differential mobility of small bowel loops and changes

in their relative intra-abdominal positions after meals (as hypothesized in ISK) may contribute.[1-5] The presence of adhesions, around which loops of small bowel might twist, has also been hypothesized[5] possibly, altered gut mobility[6] after LC in our patient may have in some way contributed to the knotting of the ileum upon itself, but a definite etiology remains obscure.

As there are no pathognomic etiological, clinical or radiological features, ileo-ileal knotting is usually not diagnosed pre-operatively;[1,2,5] these patients present with symptoms and signs of intestinal obstruction, and as is the case when strangulation occurs, progress rapidly towards septicemia and multi-organ failure due to intestinal occlusion, ischemia, and gangrene.[1-3,5] The condition is often diagnosed intra-operatively, once the knot is visualized. If the bowel is viable and strangulation has not yet supervened, untying the knot is recommended[1-3,5] since recurrence is uncommon.[1] However, this carries a risk of perforation, especially if multiple attempts are made.[1-3,5] If the bowel unviable, as in our patient, en bloc resection of the segment after controlled decompression of its contents followed by exteriorization or anastomosis, based on the surgeon's experience is preferred.[1-5]

References

1. Uday S, Venkata PKC, Bhargav P, Kumar S. Ileo-ileal knot causing small bowel gangrene: an unusual presentation. Int J Case Rep Imag 2012;3:28-30. doi: 10.5348/ ijcri-2012-05-121-CR-6
2. Taniguchi K, Iida R, Watanabe T, Nitta M, Tomioka M, Uchiyama K, Takasu A. Ileo-ileal knot: a rare case of acute strangulated intestinal obstruction. Nagoya J Med Sci. 2017;79:109-113. doi: 10.18999/nagjms.79.1.109
3. Abebe E, Asmare B, Addise A. Ileo-ileal knotting as an uncommon cause of acute intestinal obstruction. J Surg Case Rep. 2015; 8: 1 - 2.doi: 10.1093/jscr/rjv102
4. Kalachelvan L, Perumal SU, Ross K, Subramanian B. Ileo-Ileal Knot Causing Intestinal Obstruction – A Case Report. OSR-JDMS 2016; 15: 26 – 9. DOI: 10.9790/0853-150732629
5. Gopivallabh MM, Jaganmaya K, Hanumanthaiah KS, Babannavar P, Crithic V. Ileoileal Knot as a Content of Obstructed Hernia: What Are the Odds? Iran J Med Sci. 2016; 41:238–240
6. Madacsy L, Dubravcsik Z, Szepes A (2015) Postcholecystectomy Syndrome: From Pathophysiology to Differential Diagnosis - A Critical Review. PancreatDisordTher 5: 162. doi:10.4172/2165-7092.1000162

Disseminated Histoplasmosis Presenting as Lower Gastrointestinal Bleeding in an Immunocompetent Individual: A case report and review of the literature

Subhashish Das[1]
Atul Kakar[2]
Sabina Langer[3]
Samiran Nundy[1]

[1]Department of Surgical Gastroenterology and Liver Transplantation, [2]Department of Medicine, [3]Department of Hematology, Sir Ganga Ram Hospital, New Delhi, India.

Corresponding Author: *Dr Subhashish Das*
Email: subhamsubham1@yahoo.co.in

Histoplasmosis is an important systemic fungal infection caused by a dimorphic fungus, Histoplasma capsulatum. In India, the disease has been reported from several parts of the country - most cases being from eastern India, considered to be endemic for the disease. The causative fungus is present in the soil, acquired through inhalation, and has three types of manifestations - acute primary, chronic cavitary, and progressive disseminated histoplasmosis. Among the forms of histoplasmosis, Disseminated histoplasmosis (DH) is the rarest and generally found in immune-compromised individuals. It can manifest as varying symptoms because of the involvement of various organ systems. Here we present an immunocompetentpatient with disseminated histoplasmosis who presented withlowergastrointestinal(GI) bleeding.

Case Report

A 48 year-old male from Delhi, without any previous co-morbidities, presented to us with a 15 day history of high-