are the endoscopic treatment of choice for IGV1,2 and GOV2. Endoscopic glue is associated with a significant risk of complications such as embolisation, bleeding, ulceration and extrusion.[2-4] Also, it is difficult to see varices properly in the presence of an active bleed or a large blood clot or food residue in the fundus by a conventional gastroscope. Endoscopic ultrasound (EUS) overcomes the limitations of conventional endoscopy. EUS-guided delivery of cyanoacrylate (CYA) glue enables real-time precise delivery of the glue directly into the varix lumen. Moreover, EUS also enables the use of Doppler evaluation to confirm varix obliteration simultaneously. The various EUS-guided therapies used for gastric varices include glue injection, coil placement and combination of both the above. While glue placement carries a risk of embolisation, coils larger than the size of the varix are costly. Thus, a combination of EUS-guided coil and glue decreases the cost (lesser numbers of coils are needed) and reduces the risk of embolisation (lesser amount of glue is needed and the coils act as a scaffold to retain the glue, thereby decreasing the chances of glue embolization). In a retrospective study of 152 patients, EUS-guided combined coil and glue injection of high-risk gastric varices appears to be highly effective for hemostasis in active bleeding and primary and secondary bleeding prophylaxis.[5] Once obliteration was achieved, post-treatment bleeding from varices occurred in only 3% of patients during long-term follow-up.[5] While asymptomatic glue embolization in the glue-alone group is very common,[6] combination therapy appears safe and may reduce the risk of glueembolisation. EUS-guided coil and glue has been shown to be effective in several other studies also.[6,7]

To summarise, we present a series of 3 cases where endoscopy failed and IR-guided intervention was not possible/feasible. EUS-guided therapy achieved variceal obliteration in all these cases.

References

1. Garcia-Tsao G, Sanyal AJ, Grace ND, *et al*; Practice Guidelines Committee of the American Association for the Study of Liver Diseases; Practice Parameters Committee of the American College of Gastroenterology. Prevention and management of gastroesophageal varices and variceal hemorrhage in cirrhosis. Hepatology. 2007;46:922-38.
2. Triantafyllou M, Stanley AJ. Update on gastric varices. World J GastrointestEndosc2014; 6: 168-75
3. Cheng LF, Wang ZQ, Li CZ, *et al*. Treatment of gastric varices by endoscopic sclerotherapy using butyl cyanoacrylate: 10 years' experience of 635 cases. Chin Med J (Engl) 2007; 120: 2081-5
4. Sarasvat VA and Verma A. Gluing Gastric Varices in 2012: Lessons Learnt Over 25 Years. J Clin Exp Hepatol. 2012; 2: 55–69
5. Bhat YM, Weilert F, Fredrick RT *et al*. EUS-guided treatment of gastric fundal varices with combined injection of coils and cyanoacrylate glue: a large U.S. experience over 6 years (with video) GastointestEndosc. 2016; 83:1164-72
6. Binmoeller KF, Weilert F, Shah JN, Kim J. EUS-guided transesophageal treatment of gastric fundal varices with combined coiling and cyanoacrylate glue injection (with videos). GastrointestEndosc. 2011 ;74:1019-25.
7. Romero-Castro R, Ellrichmann M, Ortiz-Moyano C, Subtil-Inigo JC, Junquera-Florez F, Gornals JB *et al*. EUS-guided coil versus cyanoacrylate therapy for the treatment of gastric varices: a multicenter study (with videos). GastrointestEndosc. 2013;78:711-21.

So Near, Yet So Far…

Rajeev S.A[1]
Ajith Thomas[1]
Neil Ananth[2]
Ebby George Simon[1]

[1]Department of Clinical Gastroenterology and Hepatology, [2]Department of Dental and Oral Surgery, Christian Medical College Hospital, Vellore, India.

Corresponding Author: *Dr Ebby George Simon*
Email: ebbysimon@gmail.com

A 33-year old male, a chronic smoker, presented to us with sudden onset of haematemesis. He had recently undergone a urological procedure and been on continuous bladder drainage. Examination revealed pulse rate of 110/minute, blood pressure 90/60 mmHg and pallor. Laboratory tests showed anaemia, thrombocytopenia and

mild elevation of transaminases. Upper endoscopy was unremarkable following which he developed another bout of haematemesis. Repeat endoscopy showed only fresh blood in the oesophagus and stomach. His hypotension worsened requiring resuscitation with intravenous fluids. As he was being stabilized, interrogation of a relative who accompanied him provided evidence that the patient had recently undergone substitution urethroplasty using buccal mucosal graft. Oral examination revealed bleeding from the upper lip. Local tamponade was immediately applied using a pressure pack. The on call dental surgeon identified the superior labial artery (**Figure 1**) as the source of bleeding which was immediately ligated and haemostasis achieved.

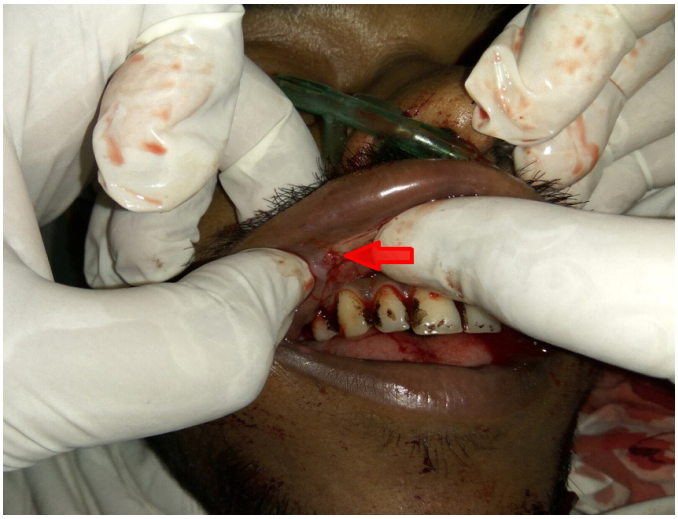

Figure 1: Superior Labial Artery (red arrow) identified as the source of bleed.

Discussion

This patient presented to us with history suggestive of haematemesis. Common causes of haematemesis include peptic ulcer, esophagitis, variceal bleed, tumours etc[1]. Rare causes include disorders of haemostasis, aortic aneurysm, infectious causes like malaria, dengue, scarlet fever, infective endocarditis and swallowed blood (epistaxis, haemoptysis, bleeding from the mouth or throat). Initial gastroscopy was unyielding but subsequent procedure showed fresh blood raising suspicion of swallowed blood. Although the details of the surgical procedure were not available, the history provided by the relative that a procedure was performed involving mouth as well as urethra gave us the clue that the bleed was probably from oral cavity. The exposed superior labial artery in the raw graft-bed site bled was the cause of bleed.

Buccal mucosal graft harvesting for urethroplasty is usually done from the cheek. It is associated with complications including bleeding, post-operative infection, pain, swelling, salivary duct disorders, restricted mouth opening, scar formation, contracture and loss of sensation due to nerve injury[2]. Bleeding is reported in 1 to 5% of patients. In a retrospective review of 128 patients from 2001 to 2015 who underwent buccal mucosal graft harvesting, bleeding from oral cavity was reported in only 1 patient (0.7%)[3]. The predictors of graft site complications were graft size, site of harvesting, open dressing at site of harvesting especially from the lower lip and avoidance of using cautery to prevent nerve injury[2].

In hindsight, we learnt that endoscopy could have been avoided had a more detailed history taking and oral examination been performed in the first place. Ultimately it was the interrogation of the patient's relative that led us to the source of bleed which was much nearer than we suspected.

References

1. Simon Anderson. Haematemesis. In: Kinirons MT, Ellis H editors. French's Index ofDifferential Diagnosis An A-Z 16th ed. New York: CRC Press; 2016. p. 238.
2. Evaluation of intraoral complications of buccal mucosa graft in augmentation urethroplasty. Akyüz M, Güneş M, Koca O etal. Turkish Journal of Urology 2014; 40(3): 156-60.
3. Buccal mucosal graft urethroplasty in men—risk factors for recurrence and complications: a third referral centre experience in anterior urethroplasty using buccal mucosal graft. Spilotros M, Sihra N, Malde S etal. TranslAndrolUrol2017;6(3):510-516.