obstruction due to the presence of several intramural cysts, which is unique in this case. Due to high resolution and proximity to the target lesion, EUS is very helpful in such cases by providing an accurate diagnosis and avoids extensive evaluation.[3] Differentiating pancreatic cancer from an inflammatory mass lesion is difficult in presence of chronic calcific pancreatitis with dense calcifications, and even EUS guided FNA has low diagnostic accuracy in the presence of chronic pancreatitis. The second case was diagnosed as groove pancreatitis. Groove pancreatitis is a form of chronic focal pancreatitis that affects the area between duodenum, bile duct, and head of the pancreas. Patients may present with pain, bile duct obstruction, or gastric outlet obstruction. The histopathological analysis shows the presence of scar tissue with fibrosis.[4] Although groove pancreatitis mimics malignancy, cystic duodenal thickening is highly suggestive of benign pathology (groove pancreatitis).[5,6]

References

1. Rana SS, Bhasin DK, Rao C, Gupta R. Intramural pseudocysts of the upper gastrointestinal tract. Endosc Ultrasound. 2013;2:194-198.
2. McCowin MJ, Federle MP. Computed tomography of pancreatic pseudocysts of the duodenum. AJR Am J Roentgenol. 1985;145:1003-7.
3. Choudhary NS, Puri R, Sud R. Gastric outlet obstruction caused by intramural duodenal pseudocysts in a young man with acute pancreatitis. Endoscopy 2015;47(S 01): E58.
4. Nanjaraj C, Basavaraj B, Manupratap N, *et al*. Groove pancreatitis-a great mimicker. BJR Case Rep. 2016;2: 20150316.
5. Zaheer A, Haider M, Kawamoto S, *et al*. Dual-phase CT findings of groove pancreatitis. Eur J Radiol 2014; 83: 1337–43.
6. DeSouza K, Nodit L. Groove pancreatitis: a brief review of a diagnostic challenge. Arch Pathol Lab Med 2015;139: 417–21.

A Case of Symptomatic Embolization after EUS Guided Coil and Glue for a Large Gastric Varix

Narendra S Choudhary
Swapnil Dhampalwar
Neeraj Saraf
Sanjiv Saigal
Rajesh Puri

Institute of Liver Transplantation and Regenerative Medicine, Medanta The Medicity, Gurgaon, Delhi (NCR), India.

Corresponding Author: *Dr Rajesh Puri*
Email: purirajesh1969@gmail.com

Endoscopic ultrasound guided coil and glue placement is advocated as a better method for gastric variceal obturation. The coils are placed before glue injection and work as scaffold to retain glue, thus decreasing risk of glue embolization. We present a case of EUS guided coil and glue embolization for a large gastric varix, the patient had symptomatic pulmonary embolization despite use of coils.

Case Report

A 53-year-old male, who was a diagnosed case of Non-alcoholic steatohepatitis, related decompensated cirrhosis was referred to our institute with history of hematemesis, 4 days back. Esophagogastroduodenoscopy done outside revealed a large fundal varix; no intervention was done due to fear of bleed after endoscopic glue as it was a large varix. After informed consent, patient was planned for endoscopic ultrasound (EUS) guided combined injection of coil and cyanoacrylate (CYA) glue. A gastroscopy (**Figure 1A**) and EUS revealed a large fundal varix, which measured 2 cm at short axis (**Figure 1B**) and 6 cm at long axis. A total of 2 coils (20 mm diameter, 14 cm length, 0.035'' thickness, Nester® embolization coil)

were placed in distal followed by proximal part of varix through 19 G EUS-FNA needle (**Figure 1C**). The coil placement was followed by injection of 1 ml of CYA and 1 ml Lipiodol combination. The Doppler after some time of procedure showed markedly decrease flow at site of injection, however, a part of varix proximal to first site of injection remained patent. One more coil and 1 ml glue + 1 ml lipiodol was further injected in remaining patent part of varix after observation for some time post first. The whole procedure was done under fluoroscopic guidance and no embolization of glue was noted during procedure (**Figure 1D**), the Doppler application showed obliterated varix (**Figure 1E**). The patient complained of low-grade fever on second day post procedure. A chest roentgenogram was done, and cultures were sent. The chest X-ray revealed starry sky appearance due to glue embolization (**Figure 1F**). Glue embolization could be seen, as mixture of glue and lipiodol (which is radio opaque) was used. Patient's work up for other causes of fever was negative and he improved with conservative management. Patient underwent a successful liver transplantation later. A chest X-ray done during pre-transplant work up, 1 month after procedure showed same findings, interestingly obturated gastric varix with coils and glue in situ was also visible (**Figure 2)**. So, it was some part of glue that got detached and caused pulmonary emboli.

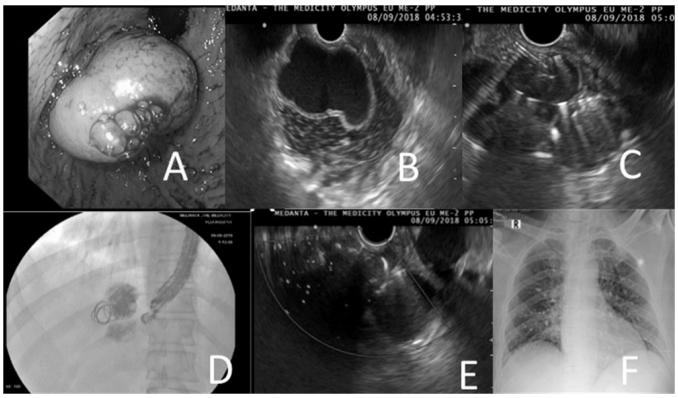

Figure 1: (A) A large gastric varix of endoscopy. (B) EUS view of large gastrc varix, note size of varix as compared to size of echoendoscope. (C) Second coil is being placed, coil artefacts are seen around needle, seco.

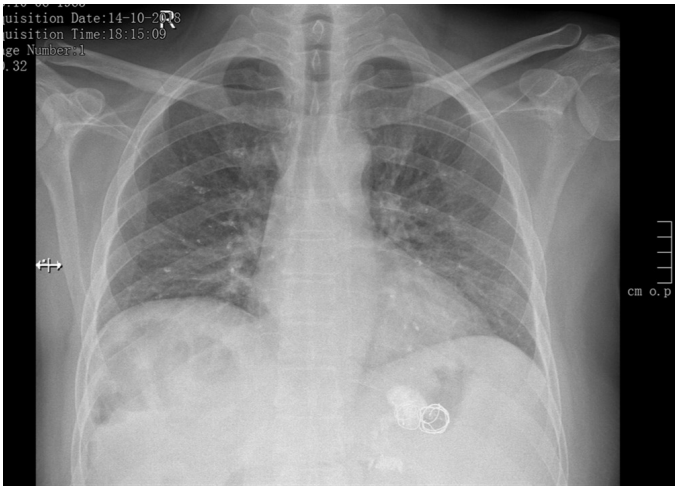

Figure 2: After one month of procedure, glue embolization can be seen in lungs, glue and coils are visible at site of gastric varix also.

Discussion

Thromboembolization of endoscopic glue injection has been shown by various studies and it may be devastating in some patients.[1] EUS guided coil placement is associated with decrease risk of embolization as compared to glue injection. In fact, glue embolization was common but remained asymptomatic.[2] Combined EUS guided delivery of coil followed by CYA serves as a cost effective (fewer coils are needed) and safe (less amount of glue is needed, and coils act as a scaffold to retain the glue, thereby decreasing the chances of glue embolization) approach. This combined therapy had few adverse events only as noted in a retrospective analysis of 152 patients by Bhat *et al*.[3] The current case highlights important aspects of EUS guided intervention for gastric varices. Adverse events are bound to happen in some patients and proper patient counselling is mandatory. Despite EUS guidance and use of coil to retain glue, some of the patients may have glue embolization as happened in index case. N-butyl-CYA has short polymerization time, thus it is common to mix lipiodol to increase polymerization time so that long EUS needle can be taken out after glue injection. Also, lipiodol makes injection of glue visible on fluoroscopy. N-octyl-CYA, which is not available here, has a longer polymerization time and thus mixing with lipiodol is not needed as shown by Bhat *et al*.[3] As happened in present case, large gastric varices need extra precautions

to prevent complications. Transjugular intrahepatic portosystemic shunt (TIPSS) placement was not done in current case as he was a candidate for liver transplantation, however, TIPSS should have a better role than EUS guided intervention in such (and selected) cases as TIPSS also solves issues of esophageal varices and ascites. We believe that safety data of EUS guided glue should be analyzed for small and large varices separately, then only we come to know about exact risk of embolization in large varices. It should be noted that we injected glue twice that might have increased risk of embolization. It was necessary as a large varix could not be obliterated by first injection and patient had history of variceal bleed, also coils were placed before each glue injection. This report raises some important but unanswered questions. Should we use EUS guided intervention (and not TIPSS) for such large varices? What is role of multiple times injection to achieve complete obturation versus single time injection and observation in follow up? It is also important to know that patients with pulmonary embolization may present as fever.[4]

Acknowledgements: none.

Funding and conflict of interest: None for any author.

References

1. Saraswat VA, Verma A. Gluing Gastric Varices in 2012: Lessons Learnt Over 25 Years. J Clin Exp Hepatol. 2012;2: 55–69
2. Romero-Castro R, Ellrichmann M, Ortiz-Moyano C *et al*. EUS-guided coil versus cyanoacrylate therapy for the treatment of gastric varices: a multicenter study (with videos) Gastrointest Endosc. 2013;78:711–721
3. Bhat YM, Weilert F, Fredrick RT *et al*. EUS-guided treatment of gastric fundal varices with combined injection of coils and cyanoacrylate glue: a large U.S. experience over 6 years (with video) Gastointest Endosc 2016; 83, No. 6 :1164-1172
4. Stein PD, Afzal A, Henry JW *et al*. Fever in acute pulmonary embolism. Chest. 2000;117:39-42

Role of Sofosbuvir Combination Therapy in Children With Chronic Hepatitis C Infection

Ira Shah[1,2]
Nikita Magdum[1]
Naman S. Shetty[1]

[1]Pediatric Liver Clinic, B J Wadia Hospital for Children, Mumbai, India. [2]Pediatric Hepatologist, Nanavati Hospital, Mumbai, India.

Corresponding Author: *Dr Ira Shah*
Email: irashah@pediatriconcall.com

Hepatitis C virus (HCV) causes both acute and chronic infection. Acute HCV infection is defined as the presence of HCV within six months of exposure to and infection with HCV. Spontaneous clearance of acute HCV infection occurs within six months of infection in 15-45% of infected individuals in the absence of treatment.[1] Most of the remaining 55% to 85% of persons will harbour HCV for the rest of their lives (if not treated) and are considered to have chronic HCV infection. HCV is a now a curable disease, and advances in HCV therapy have resulted in steadily higher cure rates. We present two children with chronic HCV infection (the first and second patient harboured genotype 1a and genotype 3 respectively) who had complete recovery with combination therapy consisting of interferon alpha 2a and sofosbuvir. The child with genotype 1a received ribavirin as well.

Case 1

A 9-year-old male suffering from thalassemia major and on regular blood transfusions every 15 days from the age of 1 was referred to our paediatric liver clinic in September 2013 for management of HCV infection. He was found to be anti-HCV antibody positive regular screening ELISA and his HCV viral load was 1212 copies/ml. HBsAg and HIV Elisa were negative. He did not have jaundice. On examination, his weight was 23kg and he had massive hepatosplenomegaly. The rest of the