the superior mesenteric artery alone for treatment of chronic mesenteric ischemia. Wien KlinWochenschr. 2016;128:109–13.

10. Cunningham CG, Reilly LM, Rapp JH, *et al*. Chronic visceral ischemia. Three decades of progress. Ann Surg. 1991;214:276–87.
11. Jimenez JG, Huber TS, Ozaki CK, *et al*. Durability of antegrade synthetic aortomesenteric bypass for chronic mesenteric ischemia. J Vasc Surg. 2002;35:1078–84.

Immunoproliferative Small Intestinal Disease with Extensive Plasma Cell Differentiation: A Rare Entity in Indian Subcontinent

Md Ali Osama[1], Seema Rao[2], Sonia Badwal[2], Amitabh Yadav[3]

[1]Department of Pathology, Lady Hardinge Medical College, New Delhi, India; [2]Department of Histopathology, [3]Department of Surgical Gastroenterology and Liver Transplantation, Sir Gangaram Hospital, New Delhi, India.

Corresponding Author: *Dr Seema Rao*
Email: seemarao1974@yahoo.co.in

Immunoproliferative small intestinal disease (IPSID) is largely prevalent in the Mediterranean region hence, also known as Mediterranean lymphoma. It represents a spectrum of histological changes of the enteromesenteric system ranging from benign lymphoid infiltrations to malignant lymphoproliferative neoplasms. It involves young adults with a peak incidence in 2nd to 3rd decade. IPSID tends to be associated with factors associated with low socio-economic status like poor nutrition, poor hygiene and frequent intestinal infections. Patients typically present with abdominal pain, malabsorption, diarrhea, steatorrhea and weight loss for a prolonged duration. Endoscopically IPSID has been characterized by loss of mucosal circular folds, a thickened, cobblestone appearance of mucosa and multiple sessile polyps. Intraoperatively, one or more distinct intestinal masses, diffusely thickened wall and/or luminal obstruction are usually observed. These features are usually noted in duodenum and jejunum, or the entire small intestinal loop, and rarely only in the ileum. Involvement of mesenteric lymph nodes is a common identifiable feature.

Case Report

The patient, a 46-year-old male, had a prolonged history with multiple hospital visits over the last 5 yrs. For the first time, he presented in 2015 (in some other hospital) with complaint of recurrent vomiting without any comorbidities. With the possibility of subacute intestinal obstruction, CT scan of abdomen was done which showed circumferentially thickened jejunal segment with narrowed bowel lumen. No active treatment was given, and the patient had a relatively uneventful period for next few years. In 2018, he again consulted the gastroenterologist with complaints of pain abdomen and vomiting. Enteroscopy revealed a stricture, hence CT enterography was conducted which showed a 3 x 3.4 cm mass near duodenojejunal flexurealong with thickened distal jejunal and proximal ileal segment along with multiple enlarged lymph nodes. Endoscopic guided biopsy was taken from the thickened jejunal segment and was reported as IPSID on histopathological examination (**Figure 1a and 1b**). The patient was started on doxycycline for a short interval and was on regular follow up until 2019; when he showed increase in size of jejunal mass on CT scan (**Figure 2a**), following which surgery was planned and patient was operated in 2020. Intraoperatively, a large proliferative mass was noted distal to duodenojejunal flexure along with presence of another obstructing mass proximal to ileocecal junction (**Figure 2b**). Multiple variably enlarged lymph nodes in mesentery were present leading to obstruction. The patient underwent enblocexcision of the conglomerated mass containing proximal jejunal segment and lymph

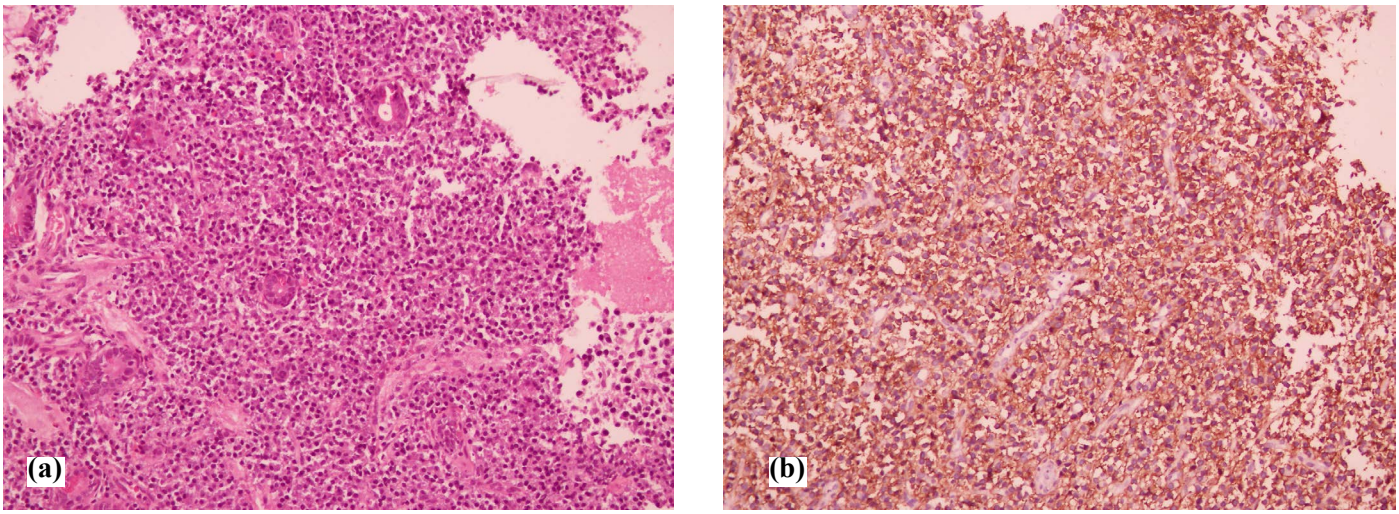

Figure 1 (a): Jejunal biopsy showing dense lymphoplasmacytic infiltrate in the lamina propria (HE 20x), (b): CD138 staining plasma cells (20x).

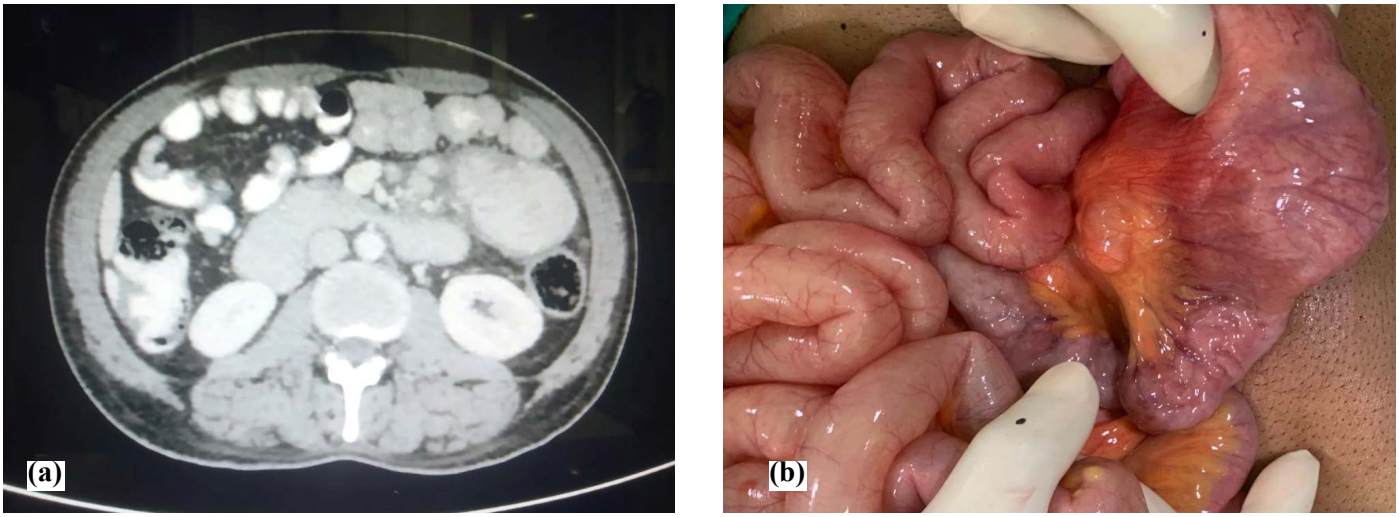

Figure 2 (a): Contrast enhanced CT abdomen showing an intraluminal enhancing lesion in proximal jejunum and a circumferential stricture in ileum, (b): Intraoperative picture showing a proliferative mass distal to duodenojejunal flexure.

nodes along with excision of the distal ileal segment. The specimen sent for histopathological examination showed a circumferential polypoidal jejunal mass of 5 x 4 cm, cut surface of which showed solid grey-white lobulated appearance. The mucosa proximal to ileocecal junction also revealed a 0.5 x 0.5 cm nodule along with multiple lymph nodes in the mesentery. Remaining ileal segment showed unremarkable mucosa. Sections examined from both lesions show ulcerated mucosa. Lamina propria was diffusely infiltrated by sheets of plasma cells / plasmacytoid cells (**Figure 3a**). These cells displayed a characteristic cartwheel chromatin and paranuclear pattern (**Figure 3b and 4a**).This cellular infiltrate was extending through muscularis mucosae into the submucosa. Few binucleate forms and singly scattered small lymphoid cells were also admixed. However, no cells exhibiting plasmablastic morphology were seen. No large atypical lymphoid cells were appreciated. Muscularis propria was free. One retrieved lymph node showed partial effacement with similar infiltrate. Remaining nodes showed reactive hyperplasia. On Immunohistochemistry, the plasmacytoid cells were diffusely positive for CD138 (**Figure 4b**),

MUM-1, EMA (**Figure 5a**) and were heterogeneously positive for CD79a. Monoclonal restriction was exhibited by Kappa positivity (**Figure 5b**). CD56 showed weak patch positivity. CD5, CD10, CD20, and PAX-5 were negative. Ki67 proliferative index was 25-30% (**Figure 5c**). The interspersed small lymphoid cells were positive for LCA (**Figure 5d**) and CD20. The diagnosis of IPSID with extensive plasma cell differentiation was rendered. On further investigations, his serum levels of IgG (11.34 g/L), IgA (2.40 g/L) and IgM (0.76 g/L) were within normal reference range; however, beta-2-microglobulin (2.5 mg/L) was slightly elevated. Since then the patient has been on regular follow up and has shown no signs of recurrence.

Discussion

IPSID / Heavy chain disease (HCD) is a rare B-cell neoplasm, which is characterized by production of monoclonal immunoglobulin heavy chains and typically no light chains. Alpha HCD being one of them presents with production of IgA. IPSID is considered to be a distinct subtype of extranodal marginal zone B-Cell lymphoma (MALToma). According to literature, the

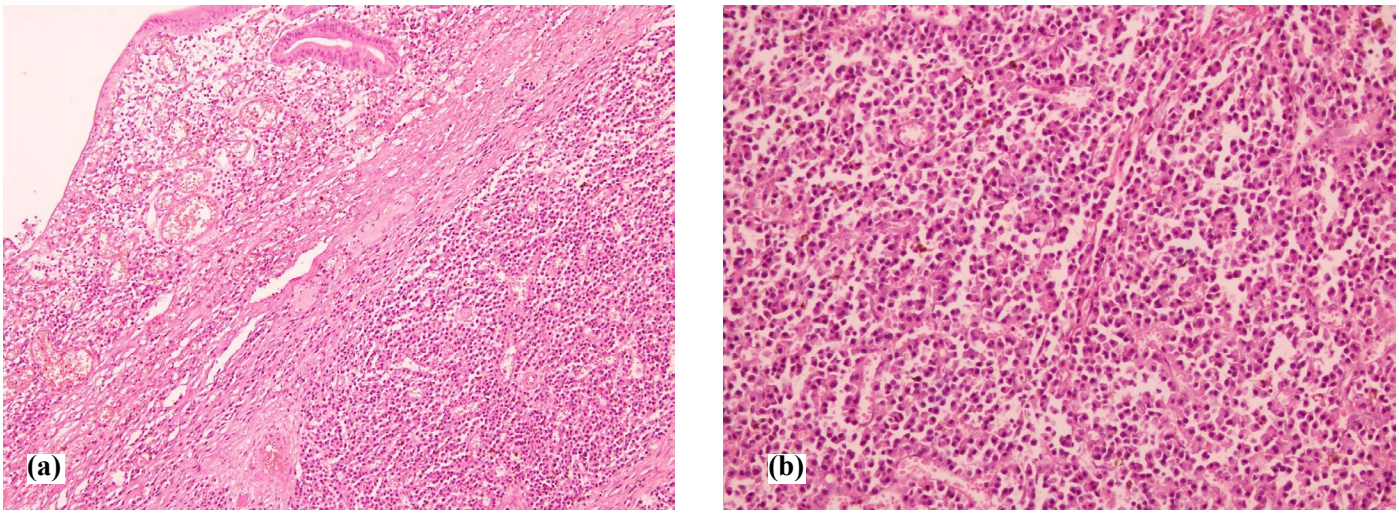

Figure 3 (a): Jejunal mass biopsy showing plasma cells extending through muscularis mucosae into the submucosa and crypts infiltrated by lymphocytes (HE 10x), (b): Sheets of plasmacytoid cells with sparsity of crypts (HE 20x).

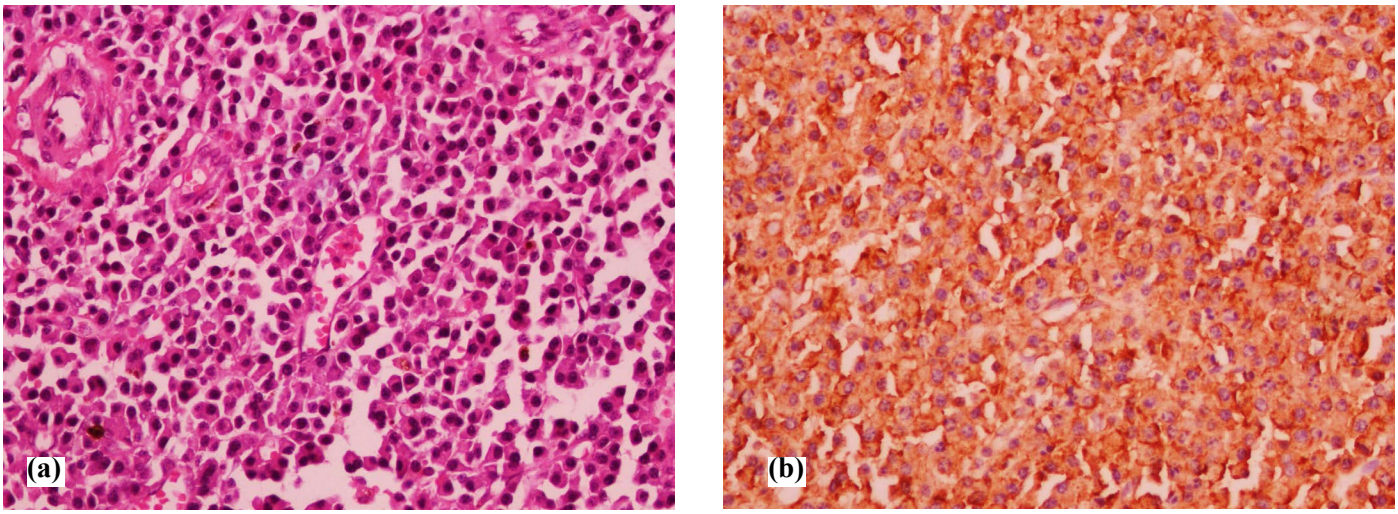

Figure 4 (a): Dense lymphoplasmacytic infiltration (HE 40x), (b): CD138 cytoplasmic staining in plasma cells (40x).

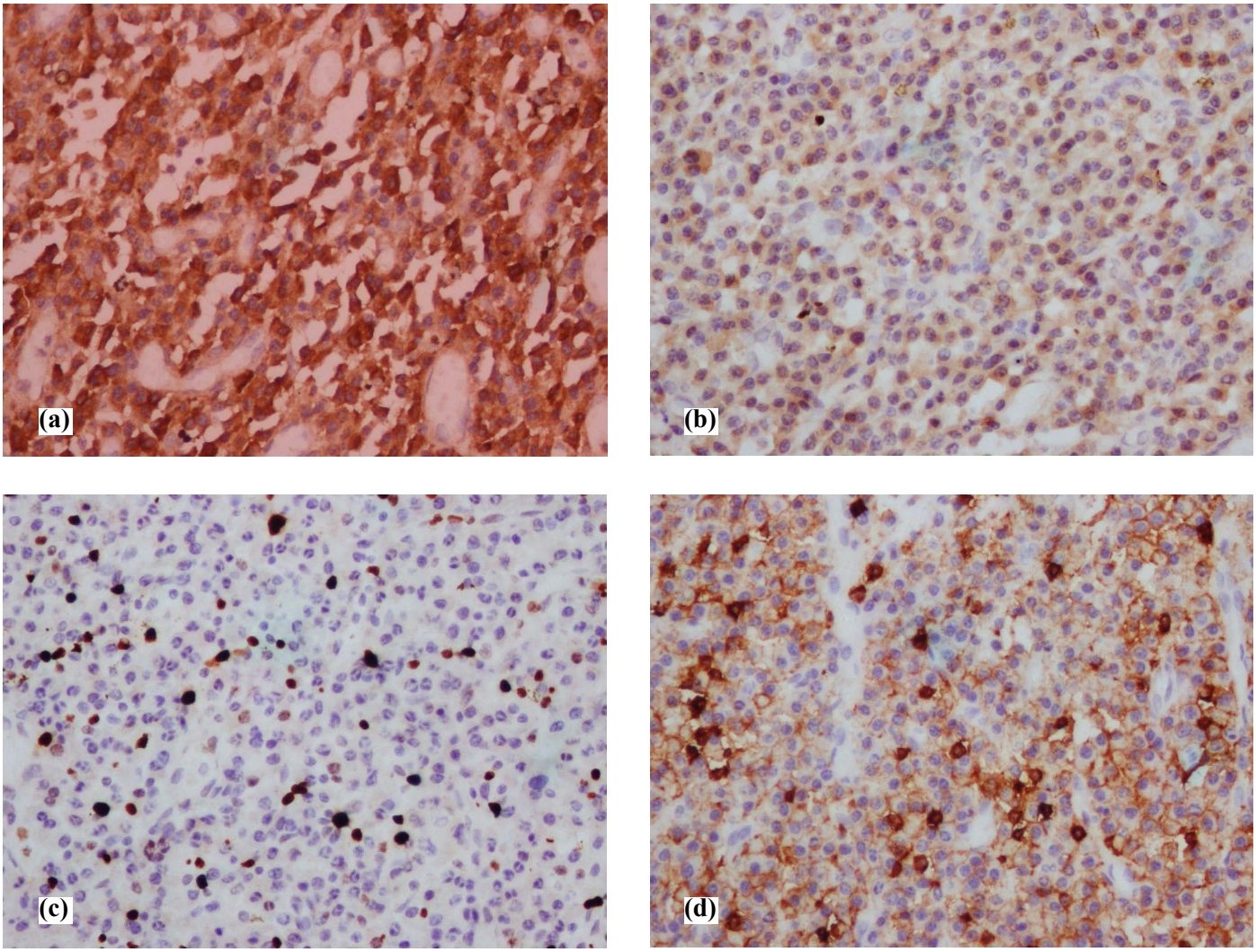

Figure 5 (a): EMA membranous staining in plasma cells an lymphoepithelial groups (40x), (b): Kappa positivity indicating monoclonality (40x), (c): Ki67 proliferative index 25-30% (40x), (d): LCA positivity (40x).

epidemiological association of gastric MALToma and H. pylori has already been established. On eradication of H. pylori with antibiotics, this lymphoma shows a remarkable regression.[1] The pathogenesis of IPSID is not completely established, however it is believed to be an outcome of chronic antigenic stimulation due to recurrent or chronic gastrointestinal infections.[1] So far, no causative agent has been unequivocally implicated, however Campylobacter jejuni, giardia and other parasites have been reported in patients with IPSID. Infection induced chronic antigenic stimulation of IgA-secreting lymphoid tissue results in neoplastic transformation of a clone of abnormal B cells, thus resulting in production of heavy chains. Subsequently, there is loss of ability to synthesize light chains. Typically, serum protein electrophoresis is normal with identifiable abnormal heavy chains on immunofixation or immunoelectrophoresis and absence of light chains. This theory has been hypothesized for the high prevalence of IPSID cases in poor population with lack of hygiene and sanitation. Our case also had a poor socioeconomic background.

Economidou *et al* in his study compared serum IgA levels of 390 dwellers of rural community and 204 residents of urban area of Greece and found out that serum IgA levels were significantly higher in people belonging to rural area as there was an increased prevalence of intestinal infections.[2] Evangelista-Leite *et al* in his review of 33 articles, evaluated a total of 76 IPSID cases and

found that patients mostly presented with elevated serum IgA (39.5%) with α-heavy chain proteins (35.5%) followed by low/ normal serum IgM and IgG (17.1%). Only in 3.9% cases stool test showed Campylobacter jejuni.[3] The occurrence of IPSID is rare in India and these cases are usually misdiagnosed as celiac disease or parasitic infestation.

Histologically, IPSID is characterized by extensive infiltration of small intestinal lamina propria with plasma cells and few lymphocytes. The inflammatory infiltrate broadens villi and separates the crypts in the early stages. In later stages, further broadening of villi with presence of loss of crypts and transmural extension of plasma cell infiltrate is observed. IPSID can give rise to all histological grades of lymphoma, namely low, intermediate and high grade. Al-Saleem *et al* in his study of 202 primary non-Hodgkin lymphomas of the small intestine in Iraq, found out that the majority of cases (38%) progressed to intermediate/ high grade lymphomas and about 12% cases progressed to low grade lymphomas, however the time period of progression was not certain.[4] Thus, for the accurate diagnosis and staging of disease, full thickness biopsy or resection of intestinal segment is advised as lymphoma may arise from deep intestinal crypts and the mesenteric lymph nodes. The differential diagnosis of IPSID includes chronic enteric infection (H. pylori or C. jejuni), celiac disease, and other types of lymphoma. Both IPSID and celiac disease are characterized by mucosal lymphoplasmacytic infiltrate and variable degree of villous atrophy. Features which favor celiac disease include villous atrophy, hyperplastic crypts, increased intraepithelial lymphocytes (IELs). Serum anti-tissue transglutaminase and anti-endomysial antibody are important diagnostic tests for diagnosing celiac disease. Also the clinical scenario and the dramatic response to gluten-free diet are important clues. Chronic enteric infection can be ruled out by microscopy, stool culture and other microbiological investigations.

The early-stage of IPSID typically responds to antibiotics, suggesting that bacterial infection could be the etiology. Our case was initially started on doxycycline therapy in 2018. Patients with high/intermediate grade disease are treated with anthracycline containing combination chemotherapy. Most untreated IPSID patients progress to diffuse large B cell lymphoma invading the intestinal wall and mesenteric lymph nodes, that may metastasize to a distant organ thus requiring multiagent chemotherapy. Surgical resection, palliative radiotherapy in combination with chemotherapy is recommended for palliation when bulky masses of high grade lymphoma are present. In our case surgical resection was done, however, no radiotherapy or chemotherapy was started. The patient has been on regular follow up. The overall 5-year survival rate of IPSID cases undergoing treatment have been around 67%.[5]

Conclusion

Although, IPSID is present in many countries around the world, it has been under reported due to its confounding morphology, convoluted diagnosis and scarce scholarly literature. The presentation of this disease may simulate that of celiac disease or any parasitic infestation and patients are usually being treated on those lines for a long period of time until being correctly diagnosed as IPSID/ NHL. Early phase of IPSID can show remission with antibiotic therapy. Patient needs long term follow-up as they may transform to aggressive lymphomas.

References

1. Sassone M, Ponzoni M, Ferreri AJM. Antibiotic treatment for bacteria-associated extranodal marginal zone lymphoma. Ann Lymphoma 2021;5:4.
2. Economidou J, Manousos O, Trichopoulos D, Triantaphyllidis J, Tsicricas T, Merikas G. Serum immunoglobulins in a rural and an urban population of Greece with special reference to immunoglobulin A. J Clin Pathol. 1979;32:1140-1143.
3. Evangelista-Leite D, AffonsoMadaloso B, Shouta Yamashita B, *et al*. Treating chronic diarrhea: A systematic review on Immunoproliferative Small Intestinal Disease (IPSID). PLoS One. 2021;16:e0253695.
4. Al-Saleem TI, Qadiry WA, Issa FS, King J. The immunoselection technic in laboratory diagnosis of alpha heavy-chain disease. Am J Clin Pathol.1979;72: 132-133.
5. Gani ABMS, Al-Mahtab M, Hossain MM, Kamal M, Rahman S. Immunoproliferative Small Intestinal Disease: First Case Report from Bangladesh. Euroasian J Hepato-Gastroenterol 2012;2:47-50.