The definite diagnosis of these lesions is difficult prior to surgical exploration as there are no pathognomonic symptoms or characteristic imaging findings. Abdominal radiographs are usually non contributory, however may reveal dilated bowel loops with air-fluid levels in the very rare patients with intestinal obstruction which may result from compression of the adjacent bowel by the cyst[6] or by mesenteric volvulus. The diagnosis may be suggested by an ultrasound of the abdomen, which may reveal a cystic lesion in relation to the bowel loops, away from the adjacent viscera. A fluid-fluid level has been reported as a characteristic finding of these cysts which results from an upper fluid level due to the chyle, and a lower fluid level due to the heavier lymph.[7] CT scan demonstrates the fluid attenuation of the lesion and its relationship with the adjacent viscera. A characteristic chyle-lymph fluid level has also been described.[8] However, in the present series, although the ultrasound and the CT scan were able to detect a cystic lesion in the region of the duodeno-jejunal flexure, away from the adjacent viscera, a definitive preoperative diagnosis of chylolymphatic cyst could not be made. Management of these cysts involves their removal which may or may not involve resection of the adjacent bowel. Most cysts can be enucleated (as in the 1st patient); however, in some this is not possible without sacrifice of the blood supply to the adjacent bowel and hence necessitates resection (as in the 2nd patient). Procedures like marsupialization and drainage are associated with high recurrence rates (as was in the 2nd case) and are best avoided.[9]

Histopathology of the resected specimen reveals either unilocular or multilocular cysts.[10] The cysts are usually lined with single layer of endothelium, and may contain lymphoid tissue and foam cells.[4,10]

Acknowledgements

We thank Dr. Kiran Chikkanahalli Subbarao for reviewing the pathology slides and Council of Scientific and Industrial Research, New Delhi for their support.

AMIT JAVED
SUJOY PAL
TUSHAR KANTI CHATTOPADHYAY

Correspondence: Dr. Amit Javed
Department of Gastrointestinal Surgery and Liver Transplantation,
All India Institute of Medical Sciences,
New Delhi - 110029, India
Email: javedamitdr@gmail.com

References

1. Moynihan BG. Mesenteric Cysts. *Ann Surg*. 1897;**26**:1–30.
2. Liew SC, Glenn DC, Storey DW. Mesenteric cyst. *Aust N Z J Surg*. 1994;**64**:741–4.
3. Beahrs OH, Judd ES Jr, Dockerty MB. Chylous cysts of the abdomen. *Surg Clin North Am*. 1950;**30**:1081–96.
4. Engel S, Clagett OT, Harrison Eg Jr. Chylous cysts of the abdomen. *Surgery*. 1961;**50**:593–9.
5. Rattan KN, Nair VJ, Pathak M, Kumar S. Pediatric chylolymphatic mesenteric cyst - a separate entity from cystic lymphangioma: a case series. *J Med Case Reports*. 2009;**3**:111.
6. Ratan SK, Ratan KN, Kapoor S, Sehgal T. Giant chylolymphatic cyst of the jejunal mesentry in a child: report of a case. *Surg Today*. 2003;**33**:120–2.
7. Fujita N, Noda Y, Kobayashi G, Kimura K, Watanabe H, Masu K, et al. Chylous cyst of the mesentery: US and CT diagnosis. *Abdom Imaging*. 1995;**20**:259–61.
8. Phillips GW, Senapati A, Young AE. Chylolymphatic mesenteric cyst: a diagnostic appearance on computed tomography. *Br J Radiol*. 1988;**61**:413–4.
9. Kurtz RJ, Heimann TM, Holt J, Beck AR. Mesenteric and retroperitoneal cysts. *Ann Surg*. 1986;**203**:109–2.
10. Handelsman JC, Ravitch MM. Chylous cysts of the mesentery in children. *Ann Surg*. 1954;**140**:185–93.

Segmental ileal dilatation in a child

Introduction

Segmental intestinal dilatation (SID) is an exceptional pathology with an unknown etiology and a misleading clinical presentation. It is a congenital condition in which the caliber of the bowel lumen increases locally without obstruction to the lumen and without deficient innervation.[1] Usually ileum is involved.[2] It is commonly referred as segmental dilatation and sometimes as segmental megaileum, ileal dysgenesis, or giant Meckel's diverticulum. We report here a case of an 8 year old boy with segmental dilatation of ileum associated with Meckel's diverticulum presenting with intestinal obstruction and previously operated in the newborn period for an omphalocele.

Case Report

An 8 year old boy presented with the history of pain abdomen and bilious vomiting of 12 hours duration and no passage of stool for one day. He had undergone primary closure for

omphalocele on first day of life. On examination he had mild dehydration and minimal abdominal distension with no area of tenderness. Plain X-ray abdomen showed multiple air fluid levels suggesting small intestinal obstruction and a provisional diagnosis of adhesive intestinal obstruction was made. He was managed conservatively with nil per orally, nasogastric tube aspiration and continuous nasogastric drainage and intravenous fluids and antibiotics. After 48 hours of admission, though he was clinically better, he had a vague mass in the upper abdomen and had not passed stools. The repeat x-ray abdomen showed an isolated loop in the right upper quadrant (**Figure 1**). He was taken up for laparotomy. Examination of the abdomen showed no evidence of adhesive obstruction and there was a localized dilatation of ileum in the region of Meckel's diverticulum and it was 7 × 6 × 6 cm in size. Meckel's diverticulum was seen in the antimesenteric border of the dilated bowel. Cut section showed normal mucosal folds in the dilated segment with ectopic mucosa in the area of Meckel's diverticulum (**Figure 2**). He underwent segmental resection of the dilated ileum and end to end anastomosis of the normal caliber bowel. He had uneventful recovery in the postoperative period. His biopsy showed normal bowel musculature and normal ganglion cells with ectopic gastric mucosa in the region of Meckel's diverticulum.

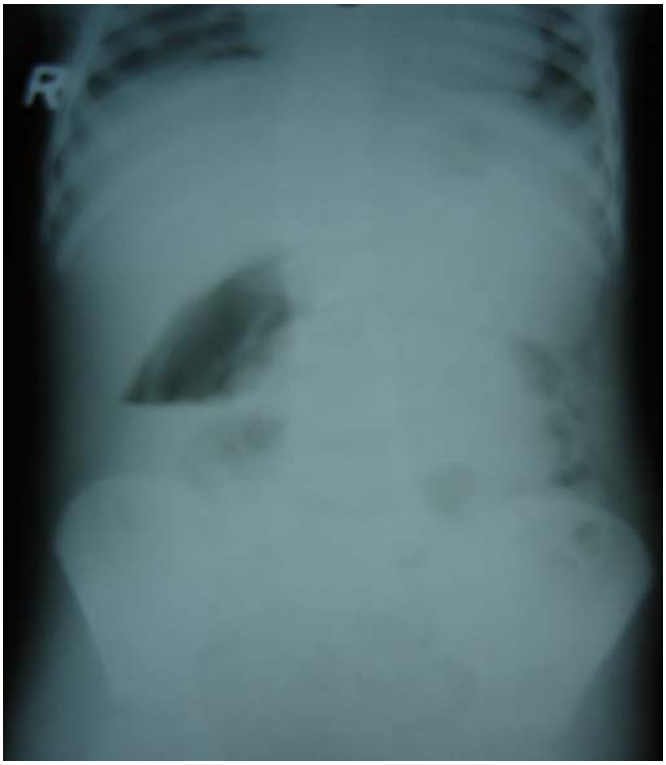

Figure 1: X-ray abdomen shows prominent loop (arrow seen) in the right upper abdomen

Figure 2: Cut section of the specimen with normal appearing mucosa and ectopic mucosa at the region of Meckel's diverticulum

Discussion

Segmental dilatation of intestine is seen in infants and young children.[1] It is characterized by a focally distended segment of bowel with three to four fold increase in size. There is abrupt transition between normal and dilated bowel and it is without an obstructing barrier, either intrinsic or extrinsic or deficient innervation.[3,4]Neonates usually present with features of intestinal obstruction within days of birth.[4] Older children present with anemia,[1,5,6] hypoproteinemia,[6] malabsorption[7] and gastrointestinal bleeding.[3] Uncommon presentations include recurrent abdominal pain,[1] bowel obstruction, non specific symptoms and incidentally detected enterolith . Few remain asymptomatic and present in their late adulthood.[2] The condition is strongly associated with omphalocele, Meckel's diverticulum and malrotation of the gut.[1] In a review of 36 cases of SID by Ratcliffe et al 50% of the cases had associated gastrointestinal tract anomalies, out of which 7 cases had Meckel's diverticulum and 6 had omphalocele and 6 had malrotation of gut.[1]

Neonates present with obstruction probably because the intestinal contents cannot easily negotiate through this segment because of ineffective peristalsis coupled with gross dilatation.[8] When older children present with intestinal obstruction, it is probably due to intermittent volvulus[1] and no delay in transit is seen in barium contrast.[2] Anemia and gastrointestinal bleed is either due to stasis ulcer or because of ectopic gastric mucosa.[3] Hypoalbuminemia and associated anemia is due to blind loop syndrome.[6,7]

In neonates the diagnosis is usually made perioperatively.[8] In children it is identified when they undergo evaluation for anemia, malabsorption or gastrointestinal bleeding. It is seen in CT as a saccular dilated loop with an air fluid level and soap bubble like contents due to faeces and air with oral contrast.[6] Definitive treatment is resection of the dilated segment and anastomosis of the normal caliber bowel leading to complete cure.[1-9]

The dilated segment varies in length from 8 to 25 cm and is often dilated 3 to 4 times the normal caliber. The dilatation is saccular or fusiform and it is in line with the normal lumen of the bowel proximally and distally. Few cases of duodenal, jejunual[1] and colonic dilatation have also been seen. Histological examination shows normal ganglion cells with normal bowel structures in majority of the cases.[4] Heterotypic gastric mucosa has been seen in some[3] with or without associated Meckel's diverticulum. Mucosal erosions with acute inflammation have also been noted.[6,9]

The etiopathogenesis of this malformation is not clear. However, most schools of thought contend an embryological defect, incriminating an extrinsic source of intrauterine intestinal compression particularly when associated with other anomalies.[1] Possibilities include a band in an exomphalos, a vitelline band arising from a Meckel's diverticulum or the vitelline vessels that involute at postpartum.[9] An alternative theory suggests that the abdominal wall itself acts as the obstructing lesion during the period of physiologic herniation. It could be due to in-utero vascular accidents.[4,6] Saha et al[4] suspected a neurogenic component and hypothesized myopathy as a possible cause.[4] But so far histo-pathological studies have been unable to resolve the issue.

Our case demonstrates an uncommon presentation of omphalocele with Meckel's diverticulum but identified at different time points. Children with segmental dilatation of ileum presenting with intestinal obstruction is very rare as they usually present with anemia or gastrointestinal bleed. Our case was misdiagnosed as adhesive intestinal obstruction because of the presenting features and the history of previous surgery. The initial picture of multiple air fluid levels followed by an isolated prominent loop is explained by the possibility of volvulus of the dilated part and correction of the same later. This case strengthens the possibility of extrinsic intrauterine compression causing SID. The clinical heterogeneity and the rarity of the lesion explain the difficulty in establishing a successful preoperative diagnosis. Fortunately, the treatment is quite straight forward and curative.

CENITA J SAM

Correspondence: Dr. Cenita J Sam
Department of Pediatric Surgery,
PSGIMS&R, Peelamedu, Coimbatore
Tamil Nadu, India
Email: cenitasivamani@yahoo.com

References

1. Ratcliffe J, Tait J, Lisle D, Leditschke JF, Bell J. Segmental dilatation of the small bowel: report of three cases and literature review. *Radiology*. 1989;**171**:827–30.
2. Javors BR, Gold RP, Ghahremani GG, Radin DR, Cho KC, Maglinte DD, et al. Idiopathic localized dilatation of ileum in adults: findings on barium studies . *AJR Am J Roentgenol*. 1995;**164**:87–90.
3. Porreca A, Capobianco A, Terracciano C, D'Onofrio V. Segmental dilatation of ileum presenting with acute intestinal bleeding. *J Pediatr Surg*. 2002;**37**:1506–8.
4. Saha S, Konar H, Chatterjee P, Basu KS, Chatterjee N, Thakur SB, et al. Segmental ileal obstruction in neonates – a rare entity. *J Pediatr Surg*. 2009;**44**:1827–30.
5. Sjolin S, Thoren L. Segmental dilatation of the small intestine. *Arch Dis Child*.1962;**37**:422–4.
6. Oberhelman AP, Herman TE, McAlister WH, Keating JP, Rollins MD, Dillon PA. CT manifestations of ileal dysgenesis. *Paediatr Radiol*. 2007;**37**:209–12.
7. Eradi B, Menon P, Rao KL, Thapa BR, Nagi B. Segmental dilatation of the ileum: an unusual cause of severe malnutrition. *Pediatr Surg Int*. 2005;**21**:405–6.
8. Ojha S, Menon P, Rao KL. Meckel's diverticulum with segmental dilatation of the ileum: radiographic diagnosis in a neonate. *Pediatr Radiol*. 2004;**34**:649–51.
9. Waters KJ, Levine D, Lee EY, Buonomo C, Buchmiller TL. Segmental dilatation of the ileum: diagnostic clarification by prenatal and postnatal imaging. *J Ultrasound Med*. 2007;**26**:1251–6.

Congenital absence of portal vein with large inferior mesenteric-caval shunt

Introduction

Congenital absence of the portal vein (CAPV) is a rare anomaly in which portal venous blood bypasses the liver through a congenital portosystemic shunt.[1-11] The drainage sites of portal venous blood include the inferior vena cava (IVC), the left renal vein and less commonly the internal iliac vein, azygos